

Upper limb

This volume is the anatomy of the upper limb commonly known as hand. It describes the distinct parts of the upper limb with details of each layer and description of the blood supply and drainage of the lymphatic system.

The topics include:

1. Surface landmarks and dermatomes (00:14:58)

- Introduction
- Upper limb - surface landmarks
 - Claw hand
 - Colles fracture
 - Elbow joint dislocation
 - Hypothenar wasting
 - Shoulder joint dislocation
 - Supracondylar fracture
 - Taking the blood pressure
 - Thenar wasting
 - Venipuncture
 - Wrist drop

2. Sternoclavicular joint and clavicle (00:05:47)

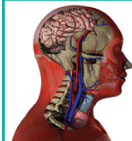
- Introduction
- Sternoclavicular joint and cervicle
 - Fracture - dislocation of the clavicle

3. Shoulder joint, scapula and humerus (00:05:01)

- Introduction
- Shoulder joint, scapula and humerus
 - Fracture - dislocation of the head of humerus
 - Rotator cuff injuries

4. Elbow joint, radius and ulna (00:07:10)

- Introduction
- Elbow joint
- Radius and Ulna
 - Pulled elbow or Nursemaid's elbow



5. Articulated hand (00:09:11)

- Introduction
- Articulated hands
 - Carpal tunnel syndrome
 - Fracture of the phalanges
 - Lunate bone dislocation
 - Scaphoid fracture - avascular necrosis of proximal end

6. Pectoral region - Pectoralis major, minor, clavipectoral fascia, deltoid (00:05:21)

- Introduction
- Pectoral region- Pectoralis major, Pectoralis minor, Clavipectoral fascia, DeltoidPancreas
 - Cleidocranial dysostosis
 - Peaud's orange

7. Axilla - Boundaries and contents (00:08:26)

- Introduction
- Axilla
 - Brachial plexus block
 - Erbs point
 - Klumpke's paralysis
 - Winged scapula

8. Front of arm - Boundaries and contents (00:10:06)

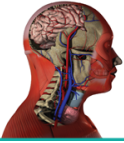- Introduction
- Front of the arm - Boundaries and contents
 - Fracture of the shaft of the humerus
 - Median nerve injury
 - Radial nerve injury
 - Ulnar nerve injury

9. Back of arm - Boundaries and contents (00:03:47)

- Introduction
- Back of arm - boundaries and contents
 - Radial nerve injury in the middle of the arm

10. Front of forearm (00:11:51)

- Introduction
- Front of the forearm
 - Fracture of the radius and ulna



11. Palm (00:08:52)

- Introduction
- Palm
 - Digital nerve block
 - Dupuytren contracture
 - Raynauds syndrome

12. Back of forearm (00:07:32)

- Introduction
- Back of forearm

13. Dorsum of hand (00:03:46)

- Introduction
- Dorsum of hand
 - Mallet finger

14. Blood supply and lymphatic drainage of upper limb (00:10:40)

- Introduction
- Blood supply and lymphatic drainage of the upper limb
 - Anastomosis around the scapula
 - Elbow joint anastomosis
 - Shoulder joint anastomosis
 - Wrist joint anastomosis