

## Lower limb

The lower limb begins with the surface landmarks and dermatomes followed by the anatomy tracing the leg from top to bottom in great detail beginning at the hip joint and ending at the sole. The blood supply and lymphatic drainage is discussed as a separate section.

The topics include:

### 1. Surface landmarks and dermatomes (00:15:28)

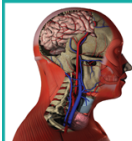- Introduction
- Surface anatomy of the lower limb - limb anterior
- Surface anatomy of the lower limb - posterior aspect
- Dermatomes of the lower limb
  - Femoral venous cannulation
  - Peripheral arterial pulsations

### 2. Hip joint and femur (00:12:18)

- Introduction
- Hip Joint
- Femur
  - Fracture of neck of femur
  - Fracture of shaft of femur
  - Hip joint dislocation
  - Radiology of the hip joint

### 3. Knee joint, tibia and fibula (00:22:25)

- Introduction
- Knee joint
- Tibia
- Fibula
  - Arthritis of the knee joint
  - Fracture of lower third of tibia
  - Fractures of the fibula
  - Knee joint aspiration
  - Knee joint dislocation
  - Patellar dislocation
  - Total knee joint arthroplasty



#### 4. Ankle joint and articulated foot (00:19:17)

- Introduction
- Ankle joint
- Articulated foot
  - Ankle joint - fracture dislocation
  - Club foot and its varieties
  - Flat foot and its varieties
  - Hammer toe

#### 5. Front of thigh, inc femoral triangle (00:10:25)

- Introduction
- Front of thigh
  - Femoral hernia
  - Saphena varix

#### 6. Medial compartment of the thigh (00:07:03)

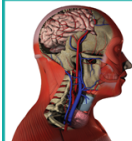
- Introduction
- Medial compartment
  - Arterial anastomosis along the medial thigh
  - Perforating injuries of the medial thigh

#### 7. Gluteal region and back of thigh (00:17:40)

- Introduction
- Back of the Thigh
- Gluteal Region
  - Cruciate anastomosis
  - Gluteus maximus - Intramuscular injections
  - Sciatic nerve injuries, Sciatica
  - Short lateral rotators of the hip
  - Trendelenberg's test
  - Trochanteric anastomosis

#### 8. Popliteal fossa and back of leg (00:14:33)

- Introduction
- Back of the leg
- Popliteal fossa
  - Achilles tendon-high heeled footwear
  - Calcaneal bursitis
  - Calcaneal tendinitis-rupture of the tendo calcaneus



## 9. Front of leg, dorsum of foot and Lateral compartment of leg (00:10:22)

- Introduction
- Front of the leg and dorsum of the foot
  - IV drips through the superficial veins of the leg
  - Peripheral arterial pulses Raynaud's disease

## 10. Sole (00:18:07)

- Introduction
- Sole
  - Calcaneal spur
  - Infections of the sole of the foot
  - Plantar reflex

## 11. Blood supply and lymphatic drainage of the lower limb (00:17:49)

- Introduction
- Arterial blood supply of the lower limb
- Lymphatic drainage
- Venous drainage
  - Catheterization of femoral artery for angiographies
  - Pedal edema
  - Thromboembolism in the deep veins of the leg